

## Analysis of Loss of Heterozygosity for Tumor-Suppressor Genes Can Accurately Classify and Predict the Clinical Behavior of Mucinous Tumors Arising From the Appendix

Vivek Maheshwari, MD,<sup>1</sup> Allan Tsung, MD,<sup>1</sup> Yan Lin, PhD,<sup>2</sup> Herb J. Zeh III, MD,<sup>1</sup> Sydney D. Finkelstein,<sup>3</sup> and David L. Bartlett, MD<sup>1</sup>

<sup>1</sup>Department of Surgery, Division of Surgical Oncology, UPMC Cancer Pavilion, 5150 Centre Avenue, Room 415, Pittsburgh, Pennsylvania 15232, USA

<sup>2</sup>Department of Biostatistics, Graduate School of Public Health, University of Pittsburgh, Pittsburgh, Pennsylvania 15261, USA

<sup>3</sup>Redpath Integrated Pathology, Inc., Pittsburgh, Pennsylvania 15212, USA

---

**Background:** Pseudomyxoma peritonei is a rare heterogeneous clinical syndrome with a variable clinical course. On the basis of the hypothesis that cumulative mutational damage can predict biological aggressiveness, we evaluated the utility of integrated histopathology and molecular analysis for patients with pseudomyxoma peritonei syndrome.

**Methods:** Tissue specimens from 23 mucinous appendiceal tumors were analyzed. DNA samples from multiple sites were analyzed for loss of heterozygosity by using a panel of 15 allelic loss microsatellite markers and *K-ras-2* point mutational damage. The fractional mutational rate (FMR), determined as the number of mutated markers divided by the total number of informative markers, was calculated by using the six most informative markers and the *K-ras-2* gene. Kappa statistics were calculated to test the association between FMR and the histopathologic classification.

**Results:** Our study included 6 female and 17 male patients with a mean age of 53.6 years and a mean survival of 43.9 months. We found an association between tumor loss of heterozygosity markers and histopathologic classification ( $P < .05$ ). In addition, there was also an association between the FMR and pathological classification as well as between the FMR and survival ( $P < .05$ ). An FMR less than .25 indicated low-grade disease, an FMR of .25 to .50 indicated intermediate grade, and an FMR greater than .5 indicated a high-grade tumor.

**Conclusions:** Mutational profiling of accumulated allelic loss and point mutational damage correlated strongly with histopathologic definitions of pseudomyxoma peritonei disease and helped to predict the prognosis of these patients. FMR, along with histopathology, offers a comprehensive classification of these rare tumors.

**Key Words:** Disseminated peritoneal adenomucinosis—Pseudomyxoma peritonei—Peritoneal mucinous carcinomatosis—Appendix—Loss of heterozygosity.

---

Mucinous appendiceal tumors are a rare heterogeneous group of neoplasms. Many of these lesions present clinically with pseudomyxoma peritonei, a

syndrome of mucinous ascites.<sup>1</sup> Although these tumors have very similar clinical presentations, their biological behavior is highly variable, ranging from a benign indolent course to a very aggressive malignant process with poor outcome. Most authors now agree that pseudomyxoma peritonei originates from a ruptured mucinous appendiceal tumor. A histopathologic classification system based on cellular features from the sampled mucinous tumor classifies the disease into three different groups.<sup>2</sup> This system includes

---

Received April 24, 2006; accepted May 10, 2006; published online September 29, 2006

Address correspondence and reprint requests to: David L. Bartlett, MD; E-mail: bartlettdl@upmc.edu

Published by Springer Science+Business Media, Inc. © 2006 The Society of Surgical Oncology, Inc.

disseminated peritoneal adenomucinosis (DPAM), representing a benign form of the disease, to peritoneal mucinous carcinomatosis (PMCA), the most aggressive form of the disease. An intermediate group is defined as specimens with PMCA with intermediate or discordant features. This classification system demonstrates significant differences in prognosis between patients with DPAM and patients with PMCA.<sup>3</sup> However, this classification system is not ideal because of the variability among different pathologists and because it may not represent the true nature of this heterogeneous disease process. For example, some patients with DPAM may present with clinically aggressive disease and die rapidly.<sup>4</sup> Another problem is that some of these tumors may show evolution to a more aggressive type during the course of the disease, and the initial histopathologic classification may not be able to predict their true malignant potential.<sup>5</sup>

The current treatment for patients with mucinous appendiceal tumors with pseudomyxoma peritonei is cytoreductive surgery and some form of intraperitoneal chemotherapy.<sup>6-8</sup> However, the extent and timing of surgery and the type of chemotherapy administered remain controversial. These procedures have significant morbidity and mortality because of the aggressive surgical debulking required.<sup>6,9</sup> In addition, this treatment may not be appropriate for patients with benign disease. Thus, it would be useful to supplement additional prognostic information obtained from histopathologic analysis. Gene analysis has been explored to provide further information to assist tumor diagnosis and prognostication. Tumor-suppressor gene loss is a frequent event in many forms of human cancer.<sup>10,11</sup> It has been recently shown that a panel of liver cancer-associated tumor-suppressor gene markers of allelic loss could serve as a representative indicator of gene damage and provide useful information to more accurately stage and predict the outcome of patients with hepatocellular carcinoma.<sup>12</sup> On the basis of the hypothesis that cumulative mutational damage can predict biological aggressiveness, we evaluated the utility of an integrated histopathologic and molecular analysis for appendiceal tumors presenting as pseudomyxoma peritonei. This would provide an objective assessment in which future recurrences could be analyzed to predict the changing behavior of the disease.

## MATERIALS AND METHODS

This study was conducted after appropriate approval was obtained from the institutional review

board of the University of Pittsburgh Medical Center with oversight authority for medical research. Tissue block and histological slides of 25 patients with mucinous appendiceal tumor presenting between 1989 and 2003 were collected. Of these patients, 23 had extra-appendiceal intraperitoneal disease or pseudomyxoma peritonei, and 2 had disease limited to the appendix only. Original pathology reports for each patient were reviewed. Because inconsistent terminology was used to describe these tumors, all histology slides were reviewed by one gastrointestinal pathologist and were classified as DPAM, intermediate, or PMCA according to the classification scheme proposed by Ronnett et al.<sup>2</sup>

Molecular analysis was performed without knowledge of the specific diagnosis or clinical outcome. Four serial 4- $\mu$ m-thick unstained histological sections were prepared for each case from blocks chosen to best represent the lesion. Using the original hematoxylin and eosin-stained sections as a guide, three to five tissue samples from various sites of involvement showing the greatest anaplasia were microdissected from each unstained slide by hand under stereomicroscope (Olympus SZ-40, Center Valley, PA) observation. The site of greatest anaplasia was selected for loss of heterozygosity (LOH) analysis because it is most likely to represent tumor behavior and outcome. Microdissected samples also included nonneoplastic tissue separate from lesional tissue when available. The normal tissue sample was taken carefully to be no larger in size and to include no more cells than the smallest of the various lesional microdissection targets chosen in each individual case. The purpose of this was to control for allelic dropout, which may be an interfering factor during the nucleic acid amplification step of the molecular analysis.<sup>13-15</sup> Microdissected tissue samples were placed in dilute buffer (Tris-HCl, pH 7.5) and maintained at  $-20^{\circ}\text{C}$  until genotyping could be performed.

Aliquots of each microdissected sample were polymerase chain reaction (PCR) amplified. Each sample was apportioned into 15 separate PCR reactions for individual polymorphic microsatellites situated at 9 genomic regions (1p, 3p, 5q, 7q, 9p, 9q, 10q, 17p, and 18q) in proximity to tumor-suppressor genes known or highly suspected to undergo deletional changes in colorectal carcinoma. The specific markers used with corresponding cytogenetic localization and Genbank accession information were 1p34:D1S407 (L18040), 1p34:D1S1193(L30480), 3p26:D3S2303 (L17972), 3p26:D3S1539(L16393), 5q26:D5S592 (L16423), 5q26:D5S615(L18737), 7q31:D7S1530

(L30387), 9p21:D9S251(L18726), 9p21:D9S254 (L18050), 9q24:D9S252(L17974), 10q23:D10S520 (L16357), 10q23:D10S1173(L30341), 17p13:D17S974 (G0796), 17p13:D17S1289(G09615), and 18q25: D18S5814(L17776). K-ras-2 point mutations were identified by PCR amplification of microdissected tissue targeting the first exon of the gene centered on codons 12 and 13, where mutational changes occur. The PCR product was purified by filter centrifugation (Qiagen) and then underwent DNA cycle sequencing with dideoxy chain termination. PCR amplification was designed to generate an amplicon of less than 200 base pairs long by using synthetic oligonucleotide primers flanking each microsatellite.

Oligonucleotide primers were created with 5' fluorescent moieties (FAM, HEX, and NED) suitable for automated fragment analysis. The PCR products were analyzed by capillary electrophoresis according to the manufacturer's instructions (ABI3100; Applied Biosystems). Allele peak heights and lengths were used to define the presence or absence of allelic loss imbalance for a given sample. The specific criteria used to assign the absence of allelic loss are described below. Nonneoplastic microdissected tissue samples were first evaluated for informative status with respect to individual alleles. When a particular microsatellite marker in a nonneoplastic tissue sample manifested only a single peak, the case was designated as noninformative for that particular marker. Thresholds for significant allelic imbalance were determined beforehand in extensive studies using normal (nonneoplastic) specimens representing each unique pairing of individual alleles for every marker used in the panel. Peak height ratios falling outside of 2 SD beyond the mean for each polymorphic allele pairing were assessed as showing significant allelic imbalance. In each case, a buccal brush or alternative source of nonneoplastic DNA was available to establish informativeness status and then to determine the exact pattern of polymorphic marker alleles to be  $< .5$  or  $> 2.0$ , as previously described.<sup>12</sup> Having established significant allelic imbalance, it was then possible to calculate the proportion of cellular DNA that was subject to hemizygous loss. For example, a polymorphic marker pairing whose peak height ratio was ideally 1.00 in normal tissue with a standard deviation in nonneoplastic tissue of .23 could be inferred to have 50% of its cellular content affected by hemizygous loss if the peak height ratio was .5 or 2.0. Having established the presence of allelic imbalance based on the polymorphic allele ratio as described previously, the microdissected sample was designated as LOH (positive LOH).

For most patients, more than one peritoneal disease specimen was analyzed. However, for the final analysis, only one specimen per patient was included. Either the most representative specimen or the specimen showing the most mutations was included. For most patients, mutational profiles between different target tissue samples were consistent. Statistical analysis was performed by using the SAS 8.2 package (SAS Institute, Cary, NC). Marginal association between each marker and histopathologic classification was tested by Fisher's exact test. Six genes that showed a significant association with the tumor pathology ( $P < .05$ ) were chosen, in addition to the K-ras-2 gene, to be used in the calculation of the fractional mutational rate (FMR). The FMR is defined as the number of mutated markers divided by the total number of informative markers. A multiple logistic model was fitted to the data to test the association between the histopathologic classification and the FMR calculated. Furthermore, tumors were classified on the basis of their FMR values. An FMR score  $< .25$  indicated low-grade disease, an FMR between .25 and .50 indicated intermediate grade, and an FMR  $> .5$  indicated a high-grade tumor. Proportional hazard models were used to test the association of FMR-based classification and overall survival. Kappa statistics were calculated to test the agreement between the reviewed histopathologic classification and the classification based on FMR.

## RESULTS

Mutational analysis was performed for 23 patients with mucinous appendiceal tumors and pseudomyxoma peritonei syndrome. There were 6 female and 17 male patients with a median age of 53.6 years (range, 27–90 years) at presentation. Complete follow-up information was available for 22 patients. One patient was lost to follow-up after 27 months. On review of histology, 6 cases were classified as DPAM, 7 as having intermediate features, and 10 as PMCA. Of these patients, 22 underwent at least 1 tumor-debulking procedure with or without intraperitoneal chemotherapy. At last follow-up, all patients with DPAM were alive, although the one patient who was lost to follow-up belonged to this group. In the intermediate group, three patients died of their disease during the follow-up period. In the PMCA group, six patients died of their disease. The overall mean survival was 43.9 months, and the overall median survival was 34 months (Fig. 1).

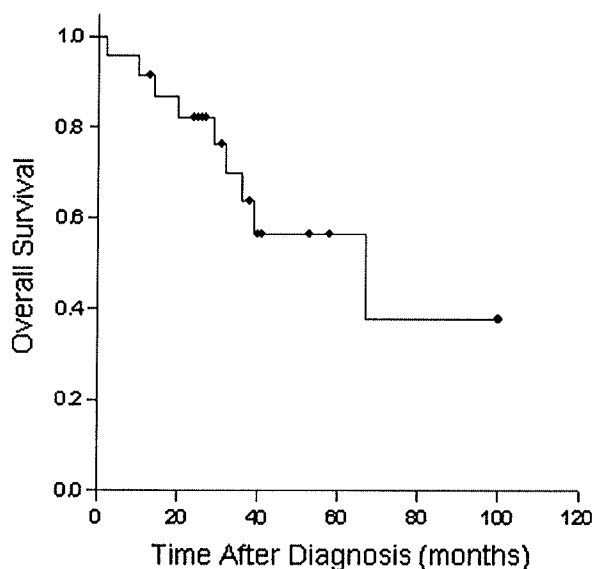


FIG. 1. Overall survival for all 23 patients in the analysis. The overall mean survival was 43.9 months, and the overall median survival was 34 months.

Six markers—3p26, 5q26, 7q31, 9q24, 17p13, and 17p13—were found to be most frequently mutated in our population ( $P < .05$ ). In Table 1, FMR was calculated for each patient by using these six markers and *K-ras-2* gene mutational changes. The predicted diagnosis of each specimen using FMR calculations was compared with the original reviewed pathology (Table 1).

An FMR of  $< .25$  was predictive of a low-grade tumor or DPAM. An FMR between  $.25$  and  $.50$  correlated with intermediate-grade tumors, and an FMR  $> .50$  indicated a high-grade tumor or PMCA. FMR calculation to predict diagnosis agreed with the histological classification in 18 patients. The  $\kappa$  statistic for testing the agreement between these two methods was calculated to be  $.67$  ( $P < .0001$ ), thus suggesting that the two methods agreed with each other. Of the five cases with mismatches, four were predicted to be DPAM instead of intermediate grade, and all patients are alive and well at 26, 31, 40, and 170 months after their diagnoses. Another patient's analysis predicted PMCA instead of intermediate grade, and this patient died of disease at 10 months. The clinical outcomes of these patients correlated more closely with their FMR calculations than with their histological classification.

The overall survivals among the three classification groups were compared by using the reviewed pathology (Fig. 2) and the FMR calculation (Fig. 3). The FMR predicted disease-specific survival. Increasing

FMR indicated a poorer prognosis ( $P < .05$ ). The age and sex did not affect survival. The effect of surgical debulking or intraperitoneal chemotherapy on survival could not be detected because of small sample size and short follow-up.

## DISCUSSION

In an attempt to accurately define the clinical behavior of patients with mucinous appendiceal tumors and pseudomyxoma peritonei, we examined LOH over a panel of 15 genes and *K-ras* mutations. These are highly polymorphic markers and are 70% to 90% heterozygous in the general population. Six of the most informative genes were selected, and an FMR was calculated. FMR was calculated for the most representative peritoneal disease of each patient. The FMR assumes that each marker contributes equally to the ultimate neoplastic phenotype. This is likely not absolutely correct because different markers may exert differential growth deregulation. Nevertheless, without a detailed understanding of molecular pathways and their alteration under different mutational changes, it is a reasonable way to compare patients with respect to overall mutational derangement.

There was a strong correlation between the calculated FMR and patient survival. Increasing FMR predicted a worse prognosis. On the basis of this score, we were able to classify patients into three groups. Low-grade tumors had an FMR score of  $< .25$ , the intermediate group had FMR scores of  $.25$  to  $.5$ , and high-grade tumors had an FMR of  $> .5$ . This postanalysis subgrouping showed a strong correlation with Ronnett's three-tier classification schema.<sup>2</sup> There was a disagreement between our model and Ronnett's classification in five patients. The clinical behavior of the tumor in all five of these patients was more accurately predicted by the FMR.

It has been previously reported that examination of LOH in patients with hepatocellular cancer can accurately predict clinical outcome.<sup>12</sup> In this article, we describe a novel classification schema for pseudomyxoma peritonei arising from mucinous appendiceal tumors that is based on LOH of tumor-suppressor genes. We also identified several limitations in the current classification of these tumors, including (1) failure of the pathologist to apply appropriate terminology and/or identify cardinal features of classification system and (2) inherent limitations of the system to accurately predict prognosis. The routine use of FMR as an adjunct to the

TABLE 1. The predicted diagnosis of each patient using FMR calculation and outcome

Patient No.	Original pathology	Reviewed pathology	FMR	Predicted pathology	Survival from diagnosis (mo)
1	Borderline mucinous cystadenocarcinoma	DPAM	.00	DPAM	AWD: 156
2	Pseudomyxoma	DPAM	.00	DPAM	NED: 27
3	Ruptured mucinous cystadenoma	DPAM	.00	DPAM	NED: 41
4	DPAM	DPAM	.17	DPAM	AWD: 58
5	Mucinous adenocarcinoma	DPAM	.00	DPAM	AWD: 25
6	Low-grade mucinous adenocarcinoma	DPAM	.00	DPAM	NED: 24
7	<b>Low-grade mucinous adenocarcinoma</b>	<b>PMCA-I/D</b>	<b>.00</b>	<b>DPAM</b>	<b>AWD: 170</b>
8	<b>PMCA</b>	<b>PMCA-I/D</b>	<b>.00</b>	<b>DPAM</b>	<b>AWD: 40</b>
9	Well-differentiated cystadenocarcinoma	PMCA-I/D	.33	PMCA-I/D	DWD: 67
10	Mucinous adenocarcinoma	PMCA-I/D	.43	PMCA-I/D	DWD: 29
11	<b>Mucinous adenocarcinoma</b>	<b>PMCA-I/D</b>	<b>.86</b>	<b>PMCA</b>	<b>DWD: 10</b>
12	<b>Mucinous adenocarcinoma</b>	<b>PMCA-I/D</b>	<b>.00</b>	<b>DPAM</b>	<b>NED: 26</b>
13	<b>Mucinous adenocarcinoma</b>	<b>PMCA-I/D</b>	<b>.00</b>	<b>DPAM</b>	<b>AWD: 31</b>
14	Poorly differentiated adenocarcinoma	PMCA	.83	PMCA	DWD: 20
15	Mucinous adenocarcinoma with signet cells	PMCA	.87	PMCA	DWD: 32
16	Pseudomyxoma	PMCA	.71	PMCA	DWD: 39
17	Moderately differentiated adenocarcinoma	PMCA	1.00	PMCA	NED: 41
18	Metastatic adenocarcinoma	PMCA	.80	PMCA	DWD: 2
19	Moderately differentiated adenocarcinoma with focal mucin	PMCA	1.00	PMCA	AWD: 38
20	Moderately differentiated adenocarcinoma	PMCA	.67	PMCA	DWD: 36
21	PMCA with neuroendocrine features	PMCA	.83	PMCA	AWD: 13
22	Mucinous adenocarcinoma	PMCA	.67	PMCA	AWD: 53
23	PMCA	PMCA	.71	PMCA	DWD: 14

FMR, fractional mutational rate; DPAM, disseminated peritoneal adenomucinosis; AWD, alive with disease; NED, no evidence of disease; PMCA-I/D, peritoneal mucinous carcinomatosis with intermediate or discordant features; PMCA, peritoneal mucinous carcinomatosis; DWD, dead with disease.

Patients with mismatches reviewed and predicted pathology are in bold.

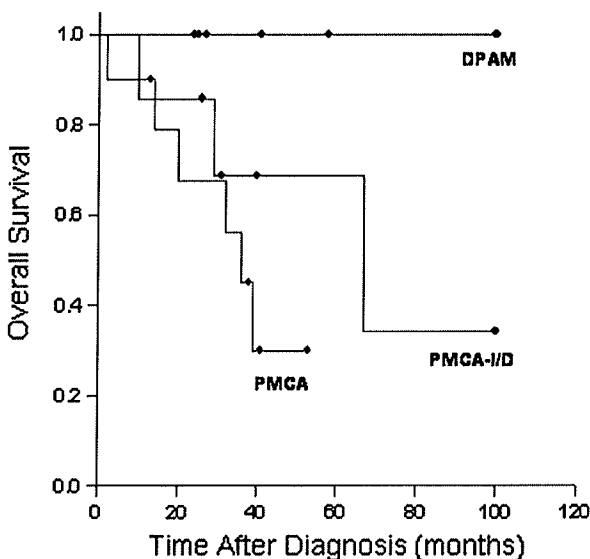


FIG. 2. Overall survival among the three classification groups determined by reviewed pathology. DPAM, disseminated peritoneal adenomucinosis; PMCA, peritoneal mucinous carcinomatosis; PMCA-I/D, peritoneal mucinous carcinomatosis with intermediate or discordant features.

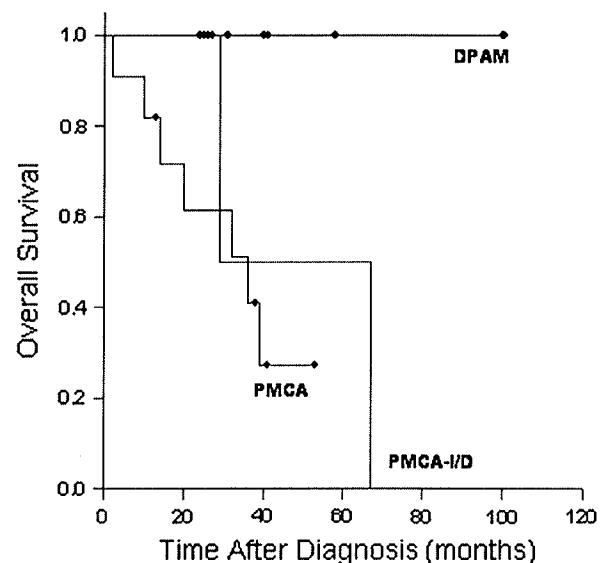


FIG. 3. Overall survival among the three classification groups determined by fractional mutational rate calculation. DPAM, disseminated peritoneal adenomucinosis; PMCA, peritoneal mucinous carcinomatosis; PMCA-I/D, peritoneal mucinous carcinomatosis with intermediate or discordant features.

current classification system may improve overall diagnostic accuracy and provide more accurate prognostic information.

Improved survival for patients with pseudomyxoma peritonei has been reported after aggressive cytoreductive surgery and hyperthermic intraperito-

neal chemotherapy.<sup>7,16-19</sup> These procedures have significant morbidity and mortality because of the aggressive nature of the treatment.<sup>6,9</sup> Support for this therapy has recently been criticized as being based on comparisons of overall survival in patient groups with diverse or poorly defined pathologic subtypes. These authors have suggested that improved survival is a result of selection of favorable pathologic subgroups (DPAM) rather than the specific treatment. Future clinical studies may benefit from molecular genotyping of the tumors to objectively ensure uniformity among patients.

We found very little uniformity among community pathologists in the use of the Ronnett system in our 23 patients. The original pathologists used inconsistent and confusing terminology to describe the tumors. Tumors were variably reported as pseudomyxoma, cystadenoma, and adenocarcinoma with mucinous features with different grades. Of the 23 cases examined in this study, 10 distinct histopathologic diagnoses were identified. There was no attempt to use the intermediate group defined by Ronnett et al. among the community pathologists. Instead, most of these were labeled as adenocarcinomas with the modifiers "well differentiated" or "mucin producing." When each of these tumors was reviewed by a single experienced gastrointestinal pathologist experienced with the Ronnett classification system, 21% (5/ of 23) of the diagnoses were changed to a different prognostic category. Four of these were downgraded to DPAM from adenocarcinoma variants, and one pseudomyxoma was reclassified as PMCA. These misclassifications have significant repercussions, because the overall survival between DPAM and adenocarcinoma can differ by 10 years.<sup>3</sup> The misclassification of four cases of DPAM as adenocarcinoma highlights another deficiency of the current classification schema, because it overemphasizes subjective assessment of mucin production and the cellularity of the tumor rather than the degree of malignancy of the epithelium. Some pathologists continue to consider any appendiceal tumor associated with epithelial cells beyond the appendix as PMCA.<sup>20</sup> In the Ronnett classification system, DPAM can be associated with significant cellularity as long as the degree of atypia is low.

Recently, a clinically aggressive variant of DPAM with an invasive disease process has been described.<sup>4</sup> In this cohort, all patients had undergone extensive cytoreductive therapy and had been diagnosed with DPAM histologically. Despite the same histology, marked differences in survival were noted, with a 5-year survival of 31%, compared with the expected 75% 5-year survival with DPAM. This subgroup

could not be distinguished on the basis of the current classification scheme. In addition, the authors found no difference in the expression of MUC1 and MUC2 mucin antigens between these tumors, despite evidence that increased expression of these mucins is associated with poor prognosis in colorectal adenocarcinoma.<sup>21,22</sup> Thus, the authors concluded that further investigation of pseudomyxoma peritonei at a molecular and genetic level may help to formulate a more comprehensive classification.

On the basis of the results of our study, we believe that cumulative mutational damage can accurately predict prognosis in this disease entity. Currently we are performing this analysis prospectively to predict prognosis and plan treatment. Longer follow-up and further studies involving more patients are required to validate these results. This molecular and genetic analysis, along with pathologic classification, can provide a more comprehensive classification of these tumors.

## REFERENCES

1. Sugarbaker PH, Ronnett BM, Archer A, et al. Pseudomyxoma peritonei syndrome. *Adv Surg* 1996; 30:233-80.
2. Ronnett BM, Zahn CM, Kurman RJ, et al. Disseminated peritoneal adenomucinosis and peritoneal mucinous carcinomatosis. A clinicopathologic analysis of 109 cases with emphasis on distinguishing pathologic features, site of origin, prognosis, and relationship to "pseudomyxoma peritonei". *Am J Surg Pathol* 1995; 19:1390-408.
3. Ronnett BM, Yan H, Kurman RJ, et al. Patients with pseudomyxoma peritonei associated with disseminated peritoneal adenomucinosis have a significantly more favorable prognosis than patients with peritoneal mucinous carcinomatosis. *Cancer* 2001; 92:85-91.
4. Mohamed F, Gething S, Haiba M, et al. Clinically aggressive pseudomyxoma peritonei: a variant of a histologically indolent process. *J Surg Oncol* 2004; 86:10-5.
5. Kabbani W, Houlihan PS, Luthra R, et al. Mucinous and nonmucinous appendiceal adenocarcinomas: different clinicopathological features but similar genetic alterations. *Mod Pathol* 2002; 15:599-605.
6. Butterworth SA, Panton ON, Klaassen DJ, et al. Morbidity and mortality associated with intraperitoneal chemotherapy for pseudomyxoma peritonei. *Am J Surg* 2002; 183:529-32.
7. Deraco M, Baratti D, Inglese MG, et al. Peritonectomy and intraperitoneal hyperthermic perfusion (IPHP): a strategy that has confirmed its efficacy in patients with pseudomyxoma peritonei. *Ann Surg Oncol* 2004; 11:393-8.
8. Glehen O, Mohamed F, Gilly FN. Peritoneal carcinomatosis from digestive tract cancer: new management by cytoreductive surgery and intraperitoneal chemohyperthermia. *Lancet Oncol* 2004; 5:219-28.
9. Ahmad SA, Kim J, Sussman JJ, et al. Reduced morbidity following cytoreductive surgery and intraperitoneal hyperthermic chemoperfusion. *Ann Surg Oncol* 2004; 11:387-92.
10. Popescu NC, Zimonjic DB. Molecular cytogenetic characterization of cancer cell alterations. *Cancer Genet Cytogenet* 1997; 93:10-21.

11. Schwab M. Oncogene amplification in solid tumors. *Semin Cancer Biol* 1999; 9:319-25.
12. Finkelstein SD, Marsh W, Demetris AJ, et al. Microdissection-based allelotyping discriminates de novo tumor from intrahepatic spread in hepatocellular carcinoma. *Hepatology* 2003; 37:871-9.
13. Dreesen JC, Bras M, Coonen E, et al. Allelic dropout caused by allele-specific amplification failure in single-cell PCR of the cystic fibrosis delta F508 deletion. *J Assist Reprod Genet* 1996; 13:112-4.
14. Findlay I. Approaches for cystic fibrosis diagnosis. *Hum Reprod* 1997; 12:166-9.
15. Ray PF, Winston RM, Handyside AH. Reduced allele dropout in single-cell analysis for preimplantation genetic diagnosis of cystic fibrosis. *J Assist Reprod Genet* 1996; 13:103-6.
16. Panteix G, Guillaumont M, Cherpin L, et al. Study of the pharmacokinetics of mitomycin C in humans during intraperitoneal chemohyperthermia with special mention of the concentration in local tissues. *Oncology* 1993; 50:366-70.
17. Sugarbaker PH. Cytoreductive surgery and intraperitoneal chemotherapy with peritoneal spread of cystadenocarcinoma. *Eur J Surg* 1991; 561:75-82.
18. Sugarbaker PH, Chang D. Results of treatment of 385 patients with peritoneal surface spread of appendiceal malignancy. *Ann Surg Oncol* 1999; 6:727-31.
19. Witkamp AJ, de Bree E, Kaag MM, et al. Extensive surgical cytoreduction and intraoperative hyperthermic intraperitoneal chemotherapy in patients with pseudomyxoma peritonei. *Br J Surg* 2001; 88:458-63.
20. Misdraji J, Yantiss RK, Graeme-Cook FM, et al. Appendiceal mucinous neoplasms: a clinicopathologic analysis of 107 cases. *Am J Surg Pathol* 2003; 27:1089-103.
21. Hiraga Y, Tanaka S, Haruma K, et al. Immunoreactive MUC1 expression at the deepest invasive portion correlates with prognosis of colorectal cancer. *Oncology* 1998; 55:307-19.
22. Yonezawa S, Sato E. Expression of mucin antigens in human cancers and its relationship with malignancy potential. *Pathol Int* 1997; 47:813-30.